

Tissue Characterization of Stools and Gas Using Abdominal Ultrasonography

腹部超音波画像を用いた便およびガスの組織性状診断

Kanako Tomihara^{1‡}, Masayuki Tanabe², Junko Yotsuya³, Michiaki Takii⁴, and Masahiko Nishimoto² (¹ Grad. School Sci. Technol., Kumamoto Univ.; ² Fac. Adv. Sci. Technol., Kumamoto Univ.; ³ Fac. School Med. Sci., Fukui Univ.; ⁴ Mishima-Minami Hosp., Osaka Medical Col.)

富原香菜子^{1‡}, 田邊将之², 四谷淳子³, 瀧井道明⁴, 西本昌彦² (¹ 熊本大院 自然科学研究科, ² 熊本大院 先端科学研究部, ³ 福井大 看護, ⁴ 大阪医大 三島南病院)

1. Introduction

Many people regardless of age or gender suffer from constipation¹⁻²⁾. Constipation is medically defined as less than three stools per week. It sometimes causes serious disease such as bowel obstruction. To assess the amount and state of stools in the large intestine, interview, palpation, and X-ray inspection. Although X-ray is useful to show the intestine, this method is usually used only when bowel obstruction is suspected. Another method easier to use is required.

An ultrasound imaging is very useful for visualizing inside of the human body. Preliminarily, stools and gas in the large intestine were examined by ultrasonography³⁾. Although the ultrasonography has a potential for assessment of constipation, the diagnostic accuracy depends on the expertise of physicians.

This study's objective is to quantitatively assess the state of stools and presence of gas in large intestine using ultrasonography and to evaluate the feasibility of our proposed method by conducting in-vitro experiments.

2. Methods

Fig. 1 shows examples of 4 types of ultrasound images in large intestine: a normal stool, a hard stool, a loose stool, and gas. The proposed assessment of ultrasound images in the large intestine is focused on three characters: penetration, punctate echo, multiple reflections. In case that hard stools are accumulated in the large intestine, ultrasound drastically attenuates to the depth direction from the stool surface because hard stools contain less moisture. In case that loose stools are accumulated, the punctate echo is provided because stool particles scatter. In case that gas is accumulated with stools, the multiple reflections occur because ultrasound shuttles between the probe and the gas surface.




Fig. 1 Ultrasound images of stools and gas

Based on the above-mentioned phenomena, three quantitative characters are extracted in this method: the attenuation degree, the number of punctate echo, and the multiple reflections.

The change of brightness values to the depth direction is focused to extract the attenuation degree. The extraction algorithm of the attenuation degree is below.

1. Average brightness values of the lateral direction to cut off local characters
2. Approximate linearly the change of brightness values to the depth direction

The high-pitched approximate line shows that ultrasound drastically attenuates. Therefore, the stool hardness can be evaluated using the coefficient of the line.

The high-intensity speckles in an image are focused to extract the punctate echo. The extraction algorithm of the punctate echo is below.

1. Dilate high-intensity pixels to enhance speckles
2. Binarize by a discriminant analysis method
3. Label white pixels

The number of labels means that of punctate echo particles. Therefore, the stool looseness can be evaluated using the number of labels.

The high-intensity stripe pattern is useful to extract the multiple reflections. The extraction algorithm of the multiple reflections is below.

1. Smooth images to cut off noise by a moving average filter (low pass filter)
2. Sharpen images to enhance the stripe pattern by a sobel filter (high pass filter)
3. Average brightness values of the lateral direction to cut off local characters
4. Calculate the auto-correlation function (ACF)

The stripe pattern that is generated by gas has periodicity. The periodicity of the stripe pattern is related in the sidelobe height and sidelobe intervals of the ACF. When the stripe pattern has the periodicity, the sidelobe level is high and the sidelobe intervals are constant. In this study, the sidelobe value and the regularity of the sidelobe intervals are evaluated by the mainlobe to sidelobe ratio (MSR) and the standard deviation (SD) of the sidelobe intervals, respectively. Therefore, the gas existence is determined by the MSR and the SD of the sidelobe intervals.

3. Verification and discussion

In this section, various ultrasound images, which illustrate various stools and gas, are assessed by proposal methods. Six normal stool images, 6 hard stool images, 5 loose stool images, and 3 gas images were obtained from 3 subjects whose age range from 20's to 50's. The linear array probe of Vscan Dual Probe (GE Healthcare) was used.

First, the attenuation degree and the number of the punctate echo are investigated for evaluation of stool solidity. Proposed method about stool evaluation are applied to all images, and a scatter diagram of characters is shown in **Fig. 2**. The horizontal and the vertical axis are the attenuation degree and the number of the punctate echo, respectively. As a result, the hard stool images gather at the lower left. In constant, loose stool images gather at upper right. Most of normal stools images gather in the middle area between the hard and loose stool images. From this result, it can be said that the attenuation degree and number of the punctate echo can evaluate the stool solidity.

Secondly, the MSR and the SD of sidelobe intervals are investigated for detection of gas. Proposal method about gas detection is applied to all images. A scatter diagram between MSR and SD of sidelobe intervals is shown in **Fig. 3**. Most of the normal and the hard stool images can be separated from gas by setting a threshold for MSR. However, separation of loose stool images and gas images is difficult. It is considered that the speckle pattern in some loose stool images is similar to pattern of the multiple reflections. Therefore, it is necessary to re-examine the process about the characterization of the gas existence.

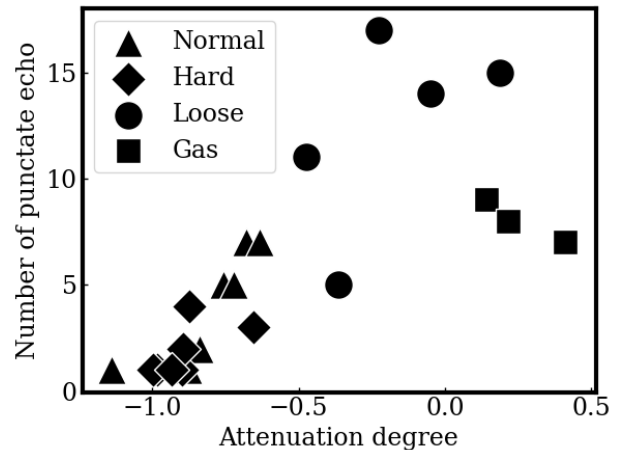


Fig. 2 Scatter diagram between attenuation degree and the number of punctate echo.

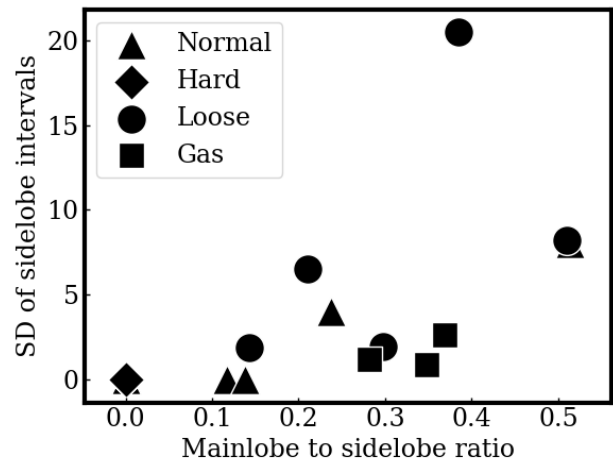


Fig. 3 Scatter diagram between MSR and SD of sidelobe intervals

4. Conclusion

In this study, some methods are proposed to quantify the character of stools and gas in the large intestine: the attenuation degree, the punctate echo, and the multiple reflections of ultrasound images. As a result, it is found that the attenuation degree and the punctate echo can evaluate the stool solidity. In future work, gas detection algorithm will be improved.

References

1. A. Horiuchi: *Geriat. Med* **50** [8] (2012) 929 [in Japanese]
2. Y. Fujii and M. Kino: *Jap. Soc. Pediatr. Gastroenterol. Hepatol. Nutr.* **25** [1] (2011) 19 [in Japanese]
3. K. Yabunaka, J. Matsuo, A. Hara, G. Nakagami, J. Sugama, and H. Sanada: *Jap. Soc. Sonographers* **38** [6] (2013) 605 [in Japanese]