

Analysis of Pancreatic Tissue Injury Caused by Ultrasonically Activated Devices

Bik Ee LAU^{1†}, Tao GAO², Aki OISHI³, Tadashi YAMAGUCHI⁴, and Hideki HAYASHI^{2,4} (¹Grad. school of Eng., Chiba Univ.; ²Grad. school of Med., Chiba Univ.; ³Fac. of Eng., Chiba Univ.; Research Center for Frontier Medical Engineering, Chiba Univ.)

1. Introduction

In recent years, couple of studies has shown that unexpected pancreatic fistula occurs more frequently in laparoscopic surgery compared with conventional open surgery for gastric cancer. Pancreatic fistula could lead to serious postoperative complications such as intraabdominal hemorrhage and/or anastomotic leakages, thus it must be avoided whenever possible.

Direct causes of pancreatic fistula have been mostly unclear in cases undergone laparoscopic gastrectomy without splenectomy or pancreaticosplenectomy. Ultrasonically activated devices (USADs) have been suspected to be associated with this complication[1,2], since USADs are widely used for lymph node dissection during laparoscopic gastric cancer surgery, and cavitation produced by USADs, could exert harmful influence onto various biological tissues[3-6]. In this study, we analyzed direct biological effects of a USAD onto pancreatic tissues using an animal model, and addressed the question of whether USADs could be the directly cause pancreatic fistula after laparoscopic gastric cancer surgery.

2. Methods

The pancreas of male, castellated 3-month-old domestic pigs weighing 30-40 kg was exposed under general anesthesia. The scissors-type laparoscopic handpiece, Harmonic Ace (ACE36J, Ethicon Endo-Surgery Japan, Tokyo) was used. Tip or side aspect of the blade was set in contact with the pancreas, and the USAD was activated for either 1, 3, or 5 seconds. As a control, an electric scalpel was activated with the tip of the blade in contact for the same duration as the USAD (Fig.1).

Each site of the device activation was macroscopically examined, and excised separately into blocks, and fixed in 10% formalin solution. Serial sections were made from each block and stained with either hematoxylin & eosin (HE), AZAN, or silver staining.

We also measured the maximum width and thickness of the tissue damage under the optical

microscopic observation.

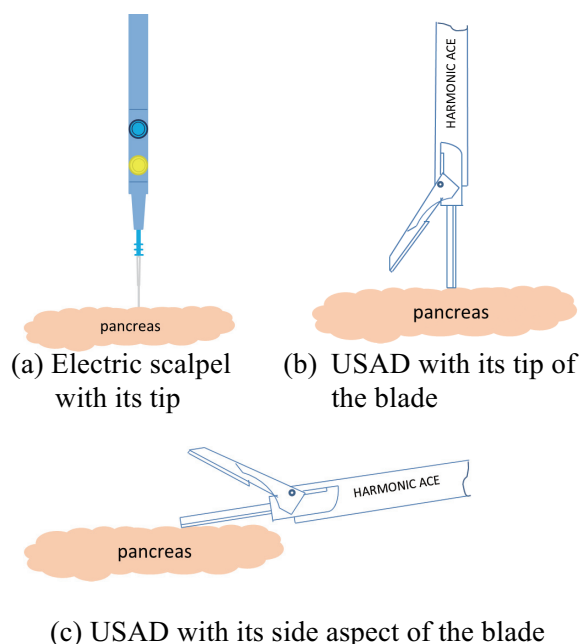


Figure 1. Activation settings of the energy devices

3. Results

Macroscopic alterations of the pancreatic surface were confirmed in all the site of device activation. Area of the damages expanded apparently as the activation time increased with either device. However, bleeding occurred only at the sites of the electric scalpel activation.

Histological analyses revealed coagulation necrosis in all the sites of device activation. However, much less protein clotting covering the necrotic sites was observed with USAD activation compared with that with electric scalpel activation. Furthermore, hyaline degeneration was observed only with USADs activations. (Fig.2)

Thickness of the tissue damages were similar between devices, however, tip of the USAD seemed to show relatively thicker tissue damages compared with the side aspect of USAD. (Fig.3). On the other

hand, the surface extent of damages caused by the side aspect of USAD was significantly larger than those with the tip of USAD or electric scalpel (Fig.4).

Obvious involvement of pancreatic ductules could not be revealed in any of the sections examined.




Figure 2. The result of the histological damage made by energy devices (5 seconds activation)

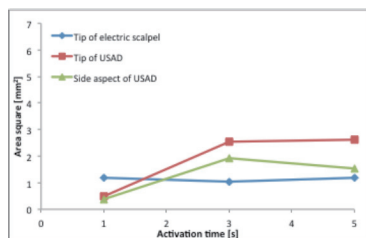


Figure 3. The maximum depth of damaged areas

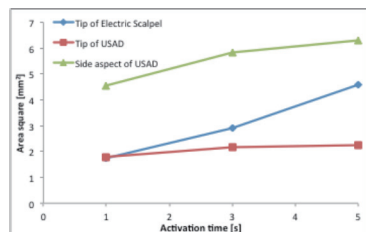


Figure 4. The maximum width of damaged areas

4. Discussion

In this study, all of the energy device setting resulted in histologically apparent tissue degeneration. However, histological appearances of degeneration were different among activation

settings. Degenerative tissue areas with electric scalpels activation were covered with thick protein clots, but much less clots were found on those with USADs activation. Although no involvement of pancreatic ductules were revealed in this study, exposed acinar cells which are not covered with protein clots presumably let off pancreatic juice. These histological findings might associate with the fact of higher incidence of pancreatic fistula after laparoscopic gastrectomies compared with open gastrectomies which are not accompanied with frequent usage of USADs around the pancreas.

Regarding the USAD tested, tip cause relatively deep penetration of degeneration as the width of it, however, side aspect cause degeneration of much wider surface area. Moreover, only one second activation results in coagulation necrosis of the tissue, suggesting that not only the tip of USAD's blade but also the side aspect of it should never be in touch with the pancreatic tissues during activation.

5. Conclusion

Biological effects on the pancreatic tissues, which were caused by surgical energy devices, were precisely investigated using an animal model. Consequently, differences in histological changes brought with conventional electric scalpel and USAD activation were elucidated. Further investigation is required to determine whether these characteristics of USADs lead to pancreatic fistula after surgeries. However, our data suggests fully cautious handling of the USAD's blade for surgeons working around the pancreas.

References

- [1] Jiang, X., et al. of laparoscopy-assisted distal gastrectomy for early gastric cancer. *Annals of surgical oncology* 19, 115-121(2012).
- [2] Obama, K., et al., Feasibility of laparoscopic gastrectomy with radical lymph node dissection for gastric cancer: from a viewpoint of pancreas-related complications. *Surgery*, 149,15-21(2011).
- [3] Maxwell JC. *A Treatise on Electricity and Magnetism*, 3rd ed., vol. 2. pp.68–73. Oxford: Clarendon (1892).
- [4] Nduka, C.C., et al. Does the ultrasonically activated scalpel release viable airborne cancer cells? *Surg Endosc* 12, 1031-1034(1998).
- [5] Hachiya, H., et al., Verification of generated cavitation of an ultrasonically activated scalpel. *Jpn J Med Ultrasonics* 39,101-111 (2012)
- [6] Hashimoto, S., et al., Analysis of tissue damage caused by ultrasonically activated device. *JSES*,15,175-181(2012).