

## A 3D Ultrasound Image Registration and Extraction of Portal Vein for Long Time Monitoring

3次元超音波像における門脈の画像位置合わせと抽出：  
長時間モニタリングのための検討

Toshiki Teratoko<sup>†</sup>, Tomohiro Ueno, Koichi Ishizu, Yasutomo Fujii,  
Tsuyoshi Shina and Naozo Sugimoto (Grad. School of Med., Kyoto Univ.)  
寺床 俊樹<sup>†</sup>, 上野 智弘, 石津 浩一, 藤井 康友, 椎名 毅, 杉本 直三 (京都大院 医)

### 1. Introduction

Important is accurate evaluation of change in a postprandial portal vein blood flow because it reflects not only hepatic but also gastrointestinal function [1]. However, few reports on long time monitoring of the portal flow by ultrasound imaging have been found. We tried to develop a new ultrasound imaging system that can monitor the portal vein continuously for a long time without manually holding of the probe. In this paper, we used a mechanical 3D probe and a hand-made probe holder as a preliminary system to acquire the serial 3D image data of the portal vein. Image co-registration was performed between the acquired multi-volume images to decrease subjects' body movement and/or respiratory displacement of abdominal organs. The co-registration errors were evaluated. Our preliminary system including 3D image co-registration method was thought to have an enough image quality to track the portal vein automatically for a long time.

### 2. Material and Methods

#### 2.1 Image Data Acquisition

A healthy subject (51 y, male) and a LOGIQ7 ultrasound system (GE Healthcare, US) with a 3.3MHz 4D3C-L probe, a mechanical 3D/4D convex type transducer, were employed. The probe was fixed on right upper abdomen with a hand-made holder using polyurethane foams (**Fig. 1**). The subject was resting in the supine position with his breath free for about 70 minutes recording. We repeated 32 times of about 105 sec 3D imaging (10 volumes/sec) following about 50 sec interval for data storage. Totally about 34000 volumes of 341 x 225 x 235 matrix size and about  $(0.32\text{mm})^3$  voxel size.

#### 2.2 Image Registration

To decrease image displacement of

abdominal organs during a long time monitoring, 3D image co-registration was performed. A volume template including a main trunk and branches of portal vein was manually selected. Each of other volume was registered to the template with only the translational adjustment in this paper. The average of absolute difference of voxel intensities (AAD) was used as the metric in the registration.

#### 2.3 Portal Vein Extraction

To reduce image noise, 536 volumes that had less than 17 of AAD value were selected, and then average volume of them was calculated. A variance volume was also calculated and was added to the average volume to enhance the contrast of the portal vein. The portal vein was extracted by thresholding of the volume image following shaping by morphological operations and 3D labeling.

### 3. Results & Discussion

#### 3.1 Image Data Acquisition

Acquisition of 70 minutes continuous 3D image data is achieved using the hand-made probe holder without any correction of the probe position nor addition of acoustic coupling materials. No significant image quality degradation was observed by visual inspection for the long scan.

#### 3.2 Image Registration

Original and registered volume sequences were shown in **Fig. 2**. The left 2 images show the B-Mode long axis view of the portal vein at different 2 time points. The right image shows virtually reconstructed M-mode image from the volume sequence. About 100 volumes were displayed. Good registration performance can be observed on the both B and M-mode images.

In **Fig. 3**, AAD of registered volume was shown. AAD values were distributed between 13 to

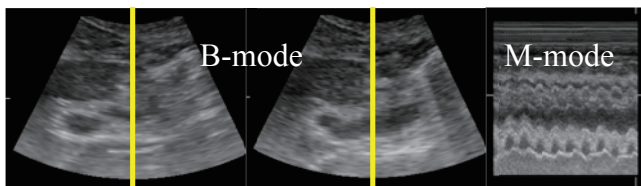
30 which were comparable with the standard deviation value of 12.11 in back ground noise region in a first volume. Because AAD value includes not only registration error or image degradation but also image noise and deformation of the abdominal organs including portal vein, it was considered that image quality was maintained during 70 minutes and that our registration process was successfully performed. In almost of the volumes with higher AAD value of about 25, acoustic shadows were observed on the portal vein.

### 3.3 Portal Vein Extraction

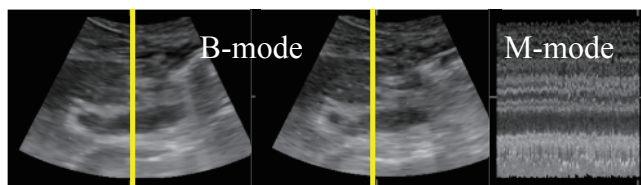
Fig. 4 shows C-mode images of umbilical portion acquired from the original and the average volume. Portal vein was clearly observed on the image of average volume. Fig. 5 shows 3D rendering image of the extracted portal vein. Structure of portal vein can be observed in 3D. Over extracted region was originated from the dark region by the acoustic shadow.



Fig. 1 Left image shows 3D probe, hand-made probe holder using polyurethane foams, and bands for fixation. Right image shows the fixed probe on a body phantom.



(a) original sequence



(b) well registered sequence

Fig. 2 (a) original sequence (b) well registered sequence  
The M-mode images were made at the yellow lines on B-mode images in the original sequence (upper) and the well registered sequence (lower).

### 4. Conclusion

The simple probe holder worked well to keep the probe at the same position on the subject's abdomen without any manual correction of its position. Image quality was also stable during the long time scan with small variation of AAD values. 3D ultrasound imaging with simple probe holder and 3D image registration was thought to be useful for long time monitoring of the portal vein. This method can be applied for long time continuous observation of portal blood flow and the other organs.

### Acknowledgment

This work was supported by JSPS KAKENHI Grant Number 26282146. This work was approved by the Medical Ethics Committee of Kyoto University.

### Reference

1. Hiroshi Nakamoto, Yoshiaki Iwamura and Takayuki Kawano at el.: Jpn. Kawasaki J Med. Welfare **J17** (2007) 147.

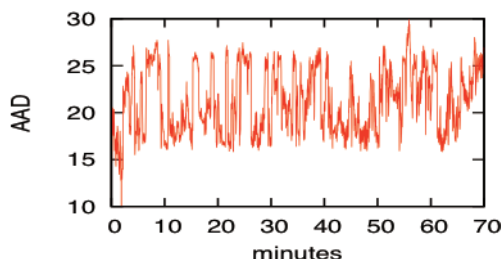


Fig. 3 Change of the AAD during the long scan is shown.

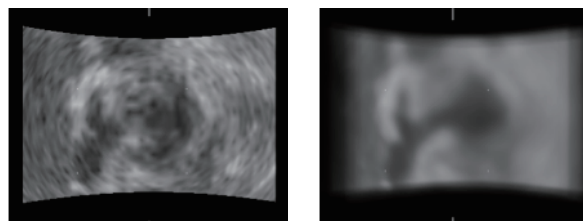


Fig. 4 C-mode images acquired from the original volume (left) and from the average volume (right) are shown. Umbilical portion appeared more clearly in the right image.

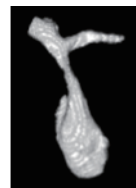

Fig. 5 The morphology of umbilical portion appears clearly in 3D.