

Automated Detection of Arterial Wall Boundary Based on Multiscale Dynamic Programming for Elasticity Imaging

弾性イメージングのためのマルチスケール動的計画法に基づく血管壁自動検出法

Yukiya Miyachi^{1,2†}, Hideyuki Hasegawa^{2,3} and Hiroshi Kanai^{3,2}

(¹Medical Systems R&D Center, FUJIFILM Corp.; ²Graduate School of Biomed. Eng., Tohoku Univ.; ³Graduate School of Eng., Tohoku Univ.)

宮地幸哉^{1,2†}, 長谷川英之^{2,3}, 金井 浩^{3,2}

(¹富士フイルム メディカルシステム開発センター; ²東北大院 医工; ³東北大院 工)

1. Introduction

The atherosclerosis has been considered to be cause of stroke and myocardial infarction. Because there are significant differences between the elasticity of normal arterial walls and those affected by atherosclerosis, the evaluation of the elasticity of the arterial wall is useful¹⁾. In series of studies on noninvasive assessment of the regional elasticity of the arterial wall, the elasticity can be evaluated from the change in thickness of the arterial wall and the blood pressure by the phased-tracking method²⁾. In the measurement of the elasticity of the arterial wall, the arterial wall boundary must be assigned beforehand. Currently, the boundary of the arterial wall is manually determined by the operator. Since the manual measurement is time consuming and results in inter- and intra-observer variability, a fast, automated method is necessary for detection of the boundary. In the present study, the multiscale dynamic programming (DP) algorithm using the boundary continuity and correlation between adjacent receive scan lines is proposed for detection of anterior and posterior wall boundaries for elasticity imaging.

2. Method

The multiscale DP algorithm is a technique for finding the boundary by maximizing a certain cost function using multiscale images, and was applied to automatic IMT (intima media thickness) detection³⁾. By applying this technique, an approximate arterial wall boundary is estimated in a coarse-scale image which is constructed through convolution of the image with a 2D Gaussian kernel. The timing at minimum diameter is detected by the phased tracking method for the approximate anterior and posterior wall positions. Under the guidance of the approximate arterial wall boundary, a finer scale is used to detect the boundary of the detailed layer structure. **Figure 1** shows an outline of the automated detection procedure.

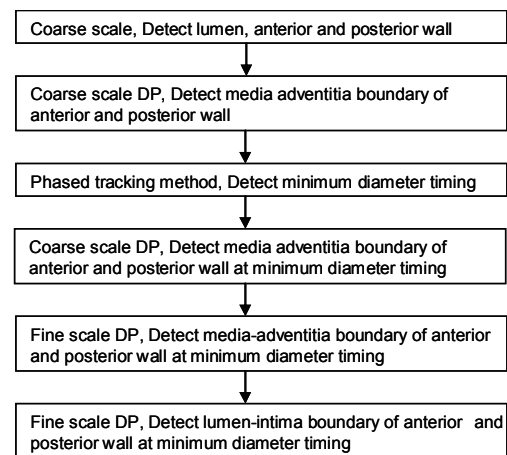


Fig. 1. Outline of automated detection procedure.

All the possible fuzzy boundary lines and their adjacent distinct lines are considered polylines with N vertices represented as a vector \mathbf{b} ,

$$\mathbf{b} = (b_1, b_2, \dots, b_{i-1}, b_i, \dots, b_N), \quad (1)$$

where b_{i-1} and b_i are horizontal neighboring boundary points. At point b_i , a local cost $C(b_i)$ is defined by

$$C(b_i) = w_1 I(b_i) + w_2 G(b_i) + w_3 R(b_{i-1}, b_i) + w_4 D(|b_{i-1} - b_i|). \quad (2)$$

where I , G , R and D are cost function terms, I represents intensity feature, G represents intensity gradient feature, $R(b_{i-1}, b_i)$ is the cross-correlation coefficient of adjacent signals, $D(|b_{i-1} - b_i|)$ is the decreasing function of the change in vertical distance between the boundary estimated and w_i is their associated weight factors⁴⁾. The cost function is defined as a sum of local costs along the polyline.

$$C_{sum} = \sum_{i=1}^N C(b_i). \quad (3)$$

The desired boundary is the optimal solution of b , which is the one that maximizes C_{sum} .

3. Results

In the following experiments, Fujifilm Fazole M US device and L10-5 linear probe were

†yukiya.miyachi@fujifilm.com

employed. The interval between scan lines is 0.15 mm. The range interval of IQ data is 0.04 mm.

Figures 2(a) and **2(b)** show original and coarse B-mode images of an artery. An intensity profile at the center line of each image is shown in **Fig. 2(c)**.

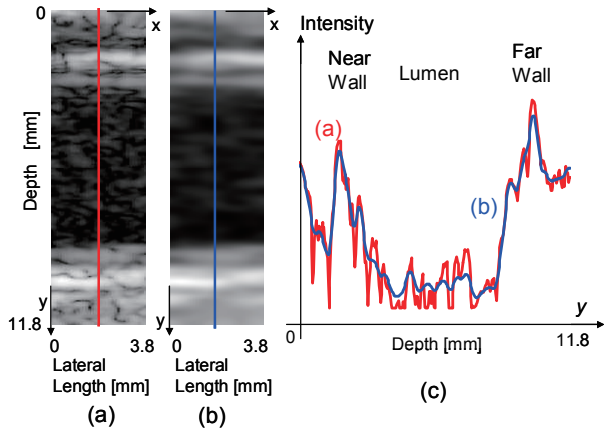


Fig. 2. (a) Original B-mode Image. (b) Coarse B-mode image. (c) Intensity profile of original and coarse B-mode images.

In the coarse B-mode image, lumen is easily determined as a darker region. DP is applied to the upper and lower parts separated by the lumen to detect media-adventitia boundaries of the anterior and posterior walls. Based on the positions of media-adventitia boundaries detected by coarse scale DP, the anterior and posterior wall boundaries are tracked by the phased tracking method and the change in diameter is estimated.

Figures 3(a) shows media-adventitia boundaries of the anterior and posterior walls on coarse B-mode image. **Figures 3(b)** shows M-mode image along the blue line on the B-mode image. The change in diameter calculated by the phased tracking method is shown in **Fig. 3(c)**. The green line shows the timing at minimum diameter.

At minimum diameter timing, firstly coarse scale DP is conducted to detect rough media-adventitia boundaries of the anterior and posterior walls. Secondary, fine scale DP is conducted using the rough media-adventitia boundaries to detect precise media-adventitia boundaries of the anterior and posterior walls. Lastly, fine scale DP is conducted using the precise media-adventitia boundary to detect precise lumen-intima boundary. The proposed method is compared with the manual tracings made by a professional expert. **Figures 4(a)**, **4(b)** and **4(c)** show original B-mode image, that with detected boundaries by the proposed method, and that with manual traced boundaries. The yellow line represents media-adventitia boundary, and the green line represents intima-media boundary. The red line is approximate media-adventitia boundary used to

determine boundaries precisely. The boundaries automatically detected by the proposed method is very close to manual tracings made by a professional expert.

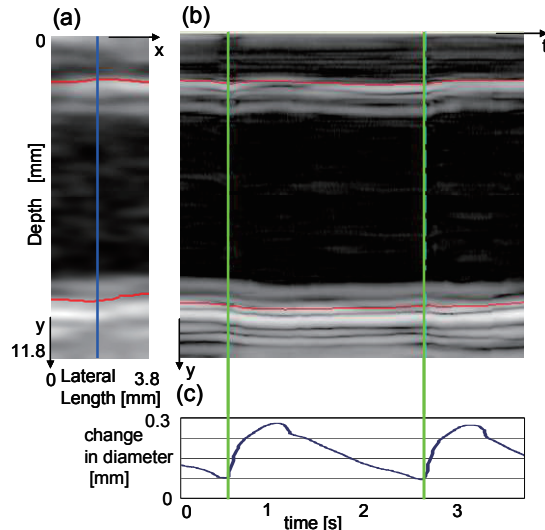


Fig. 3. (a) Media-adventitia boundaries on coarse B-mode image. (b) M-mode image along the blue line. (c) Change in vascular diameter.

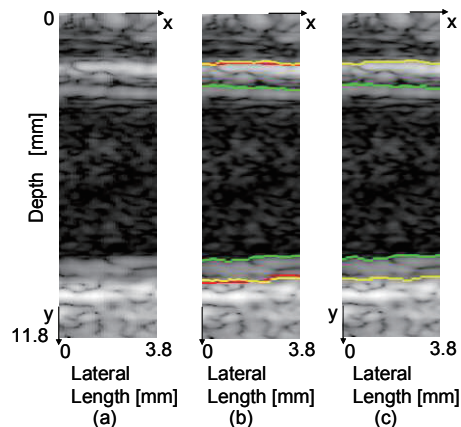


Fig. 4. (a) Original B-mode image. (b) Boundaries detected by the proposed method. (c) Manually traced boundaries.

4. Conclusion

We examined the performance of the automated border detection using multiscale DP method. This method has a potential to detect the arterial wall boundaries automatically and be useful for elasticity imaging.

References

1. P. C. G. Simons, et al.: *Circulation*, **100** (1999) 951
2. H. Hasegawa, et al.: *Jpn. J Apply. Phys.* **37**, (1998) 3101
3. .Q. Liang, et al.: *IEEE Trans. Med. Imaging* **19** (2000) 127.
4. Y. Miyachi, et al.: *Jpn. J Apply. Phys.* **40**, (2013) 3P5-14